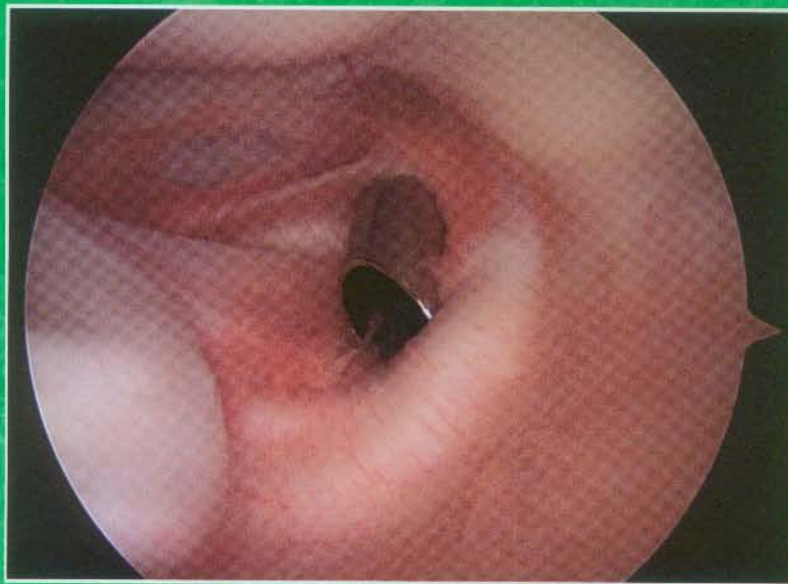

Vol 30, No 3

March 2014

ARTHROSCOPY

THE JOURNAL OF ARTHROSCOPIC AND RELATED SURGERY



www.arthroscopyjournal.org



Official Publication of the
Arthroscopy Association of North America
and the International Society of
Arthroscopy, Knee Surgery,
and Orthopaedic Sports Medicine

Elsevier

- 344 **Acute Anterior Cruciate Ligament Reconstruction With an Augmented Remnant Repair: A Comparative Macroscopic and Biomechanical Study in an Animal Model**
Guan-Yang Song, Jin Zhang, Xu Li, Xing-Zuo Chen, Yue Li, and Hua Feng

- 352 **Can Arthroscopically Harvested Synovial Stem Cells Be Preferentially Sorted Using Stage-Specific Embryonic Antigen 4 Antibody for Cartilage, Bone, and Adipose Regeneration?**
Jingting Li, Douglas D. Campbell, George K. Bal, and Ming Pei

**SYSTEMATIC
REVIEWS**

- 362 **Current Status of Evidence-Based Sports Medicine**
Joshua D. Harris, Gregory Cvetanovich, Brandon J. Erickson, Geoffrey D. Abrams, Jaskarndip Chahal, Anil K. Gupta, Frank M. McCormick, and Bernard R. Bach
- 372 **Recurrent Instability After Revision Anterior Shoulder Stabilization Surgery**
Lisa Geneva Mandeville Friedman, Michael J. Griesser, Anthony A. Miniaci, and Morgan H. Jones
- 382 **The Prevalence of Hip Labral and Chondral Lesions Identified by Method of Detection During Periacetabular Osteotomy: Arthroscopy Versus Arthrotomy**
John M. Redmond, Asheesh Gupta, Chris E. Stake, and Benjamin G. Domb
- 389 **The Learning Curve for Hip Arthroscopy: A Systematic Review**
Daniel J. Hoppe, Darren de SA, Nicole Simunovic, Mohit Bhandari, Marc R. Safran, Christopher M. Larson, and Olufemi R. Ayeni

Acute Anterior Cruciate Ligament Reconstruction With an Augmented Remnant Repair: A Comparative Macroscopic and Biomechanical Study in an Animal Model

Guan-Yang Song, M.D., Jin Zhang, M.D., Xu Li, M.D., Xing-Zuo Chen, M.D., Yue Li, M.D., and Hua Feng, M.D.

Purpose: Our purpose was (1) to compare the structural integrity and healing capacity of the acutely repaired anterior cruciate ligament (ACL) remnants and (2) to determine whether the short-term postoperative biomechanical results of the acute remnant-repairing anterior cruciate ligament reconstruction (ACLR) were superior to the conventional ACLR. **Methods:** An acute complete ACL femoral detachment model was created in 50 rabbits. The rabbits were immediately randomly allocated into the remnant-repairing ACLR group (group 1, $n = 25$) and the conventional ACLR group (group 2, $n = 25$). Each animal in both groups was subjected to unilateral ACLR with semitendinosus tendon autografts. During ACLR, the ACL remnants were acutely repaired with the femoral-tensioning technique in group 1, whereas the ACL remnants were debrided in group 2. The outcomes of the remnant were macroscopically evaluated in group 1. The remnant's structural integrity and remnant-to-graft healing capacity were divided into 3 categories (grade A, good; grade B, fair; or grade C, poor) according to 2 distinct criteria. Biomechanical tests including the anterior tibial translation test at 30° and 90° of knee flexion and tensile tests were compared between groups. All the macroscopic evaluations and biomechanical tests were performed postoperatively at week 12. **Results:** The macroscopic evaluations of the ACL remnants in group 1 ($n = 25$) showed that the remnants' structural integrity was grade A (well-maintained continuity with an adequate amount of tissue and tension on probing) in 10 specimens (40%), grade B (fairly maintained continuity with thin and slack fibers detected) in 5 (20%), and grade C (resorption with no remnant left in situ) in 10 (40%). The remnant-to-graft healing capacities among the specimens with surviving remnants (grades A and B for structural integrity, $n = 15$) were all classified as grade C (an obvious remnant-to-graft interval through the entire length of the graft). For the biomechanical tests, there were no significant differences between the groups (25 in each group) with respect to the anterior tibial translation test at 30° ($P = .15$) and 90° ($P = .91$) of knee flexion and stiffness ($P = .66$), ultimate failure load ($P = .11$), and elongation at failure ($P = .92$). **Conclusions:** In our rabbit model of ACL femoral detachment, the acutely repaired ACL remnants showed a high resorption rate, low healing capacity, and poor biomechanical properties. The acute remnant-repairing ACLR had no evident superiority over the conventional ACLR in rabbits. **Clinical Relevance:** The findings did not support the contention that the remnant-repairing ACLR, even performed in the acute setting, could produce better postoperative knee joint stability outcomes than the conventional ACLR.

Anterior cruciate ligament reconstruction (ACLR) has become a common orthopaedic surgical procedure over the past several decades, and good to

excellent results have been reported.¹⁻³ However, failure rates vary between 8% and 25%.^{4,5} Therefore efforts still need to be made to improve the surgical techniques for ACLR.

According to the literature, in complete anterior cruciate ligament (ACL) rupture cases, there are always thick and abundant ACL remnants observed during arthroscopic examinations.⁶⁻⁹ Recently, the accumulation of histologic studies concerning ACL remnants enabled us to consider a remnant-preserving ACLR as a treatment option for complete ACL tears.¹⁰⁻¹² The proposed beneficial effects of remnant-preserving ACLR, such as the biological healing potential, improved proprioceptive function, and increased biomechanical strength of the ACL grafts, may be provided by the

From the Sports Medicine Service, Beijing Jishuitan Hospital, Beijing, China.

The authors report the following potential conflict of interest or source of funding: G-Y.S. and H.F. receive support from National Natural Science Foundation of China (81071485).

Received July 6, 2013; accepted November 26, 2013.

Address correspondence to Hua Feng, M.D., Sports Medicine Service, Beijing Jishuitan Hospital, No. 31, Xin Jie Kou East Street, Xi Cheng District, 100035, Beijing, China. E-mail: fenghua20080617@126.com

© 2014 by the Arthroscopy Association of North America
0749-8063/13465/\$36.00

<http://dx.doi.org/10.1016/j.arthro.2013.11.030>

remaining vascular and neural elements within the ACL remnants.

Satisfactory clinical outcomes after remnant-preserving ACLR have been reported.^{8,13,14} However, some comparative studies also reported that no significant differences could be found between remnant-preserving ACLR and conventional ACLR in terms of postoperative clinical outcomes.¹⁵⁻¹⁷ A consensus on how to deal with the ACL remnants during ACLR is still lacking.

Meanwhile, some studies concluded that the vascular and neural elements within ACL remnants could only be found in an acute setting, beyond which they would degenerate more rapidly over time.^{18,19} Therefore it was believed that it was more reasonable to preserve the ACL remnants in an acute setting, which would provide more potential advantages to improve the clinical outcomes of the remnant-preserving ACLR. The prerequisite of these potential advantages should be a well-maintained ACL remnant after surgery. Until now, there have been no *in vivo* studies published to show the true outcomes of the ACL remnant and show the biomechanical superiority of acute remnant-preserving ACLR.

In addition, techniques for remnant-preserving ACLR may vary according to the patterns of the ACL injury.⁶ For a complete ACL tear, when a tibia-based remnant usually remains, the performance of remnant-preserving ACLR with an augmented remnant repair technique was reported to be suitable.¹⁷

Therefore we created an acute complete femoral ACL detachment animal model, aiming (1) to compare the structural integrity and healing capacity of the acutely repaired ACL remnants and (2) to determine whether the short-term postoperative biomechanical results of the acute remnant-repairing ACLR were superior to the conventional ACLR. We hypothesized that for the acute remnant-repairing ACLR, (1) the ACL remnant could be well maintained with adequate continuity, tension, and remnant-to-graft healing capacity and (2) the procedure would produce better biomechanical results than the conventional ACLR.

Methods

Study Design

Fifty adult, female New Zealand white rabbits weighing 3.0 to 4.0 kg were used in this study. Our study received permission from the Institutional Animal Care and Use Committee of our hospital. The rabbits were randomly allocated into 2 groups (25 rabbits in each group) according to random numbers generated by a computer. An acute complete femoral ACL detachment model was created in each animal. Meanwhile, an index unilateral single-strand ACLR was performed immediately. Group 1 ($n = 25$) was treated by remnant-repairing ACLR, and group 2 ($n = 25$) was treated by conventional ACLR.

Semitendinosus tendon autografts were used for all the surgeries. The operative side was selected randomly.

Before the reconstructive surgery, the length and cross-sectional diameter (measured at the midpoint of the entire length of the autografts) of the ACL autografts were measured 3 times for each animal with a Vernier caliper with 0.1-mm resolution. The mean values were then recorded. All surgeries and measurements were performed by the same surgeon.

Preparation of Acute Complete Femoral ACL Detachment Model

In this study an acute complete femoral ACL detachment model was created in each animal using the following 5 steps:

1. All animals were anesthetized with ketamine (35 mg/kg) and xylazine (5 mg/kg).
2. The randomly chosen operative side was shaved, scrubbed with povidone-iodine, and aseptically draped.
3. A 4- to 5-cm-long medial parapatellar longitudinal incision was made, and the patella was laterally subluxated.
4. The normal ACL was clearly exposed.
5. The ACL remnant was obtained by transecting the normal ACL from its femoral insertion site, whereas the remainder, including the midsubstance and the tibia insertion site, was kept intact.

Surgical Techniques

Both the remnant-repairing ACLR and the conventional ACLR were performed immediately after the acute complete femoral ACL detachment models were created.

In remnant-repairing ACLR, 3 to 4 sutures were applied to the femoral end of the remnant to provide a traction force. A single-strand semitendinosus tendon autograft was harvested from the operative knee and prepared with weaving sutures on both ends by use of two No. 4-0 Ethibond sutures (Ethicon, Somerville, NY). A 2.0-mm Kirschner wire was used as a reamer to drill the tibial and femoral tunnels. The center of the tibial tunnel was selected approximately 1 mm posterior to the native insertion site. To protect the remnant, we retracted the sutures attached to the remnant anteriorly while drilling the tibial tunnel. The femoral tunnel was drilled at the center of the femoral footprint. After tunnel preparation, we performed the ACLR with an augmented ACL remnant repair by pulling the leading sutures of the graft and the traction sutures of the remnant simultaneously into the femoral tunnel. The graft and remnant were fixed with 1 EndoButton (Smith & Nephew Endoscopy, Andover, MA), ensuring that the proximal end of the remnant reached the entrance of the femoral tunnel as much as possible. After tibial fixation with the EndoButton, the remnant and the proximal

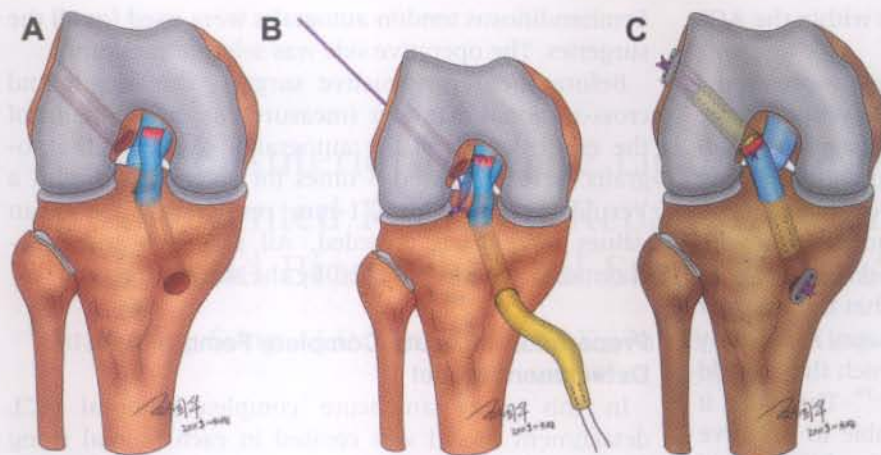


Fig 1. Surgical technique for remnant-preserving ACLR used in study. (A) An acute ACL injury model was created by transecting the normal ACL from its femoral insertion site. (B) The traction sutures of the ACL remnant and the leading sutures of the graft were pulled into the femoral tunnel simultaneously, with the proximal end of the remnant reaching the entrance of the femoral tunnel as much as possible. (C) The ACL remnant and the graft were fixed with 1 EndoButton (Smith & Nephew Endoscopy). (Reproduced with permission from Guo-hua Liu.)

articular portion of the graft were sutured together with 1 suture stitch to create a unit (Fig 1).

In conventional ACLR, the ACL remnant was completely removed. Both the tibial and femoral tunnels were made at the center of the ACL footprints. The ACL grafts were fixed with an EndoButton on both sides in the same manner as described earlier.

Postoperative Protocols

After wound closure, a bulky cotton dressing was applied to the operative knee joint. The dressing was removed 48 hours after surgery. All the animals were given prophylactic antibiotics and allowed free cage activities without restriction of motions immediately after surgery. No intra-articular anesthesia or postoperative analgesics were given to the animals. Specific care measures were taken daily to keep the cages clean and to prevent exogenous infections. At 12 weeks postoperatively, as described in other studies in the literature,^{20,21} each animal was killed with an injection of 10 mL of thiopental through the ear vein. Both knees of each rabbit were harvested from the hip joint for macroscopic evaluations and biomechanical tests.

Macroscopic Evaluations

The macroscopic evaluations included the following:

1. We evaluated the general condition of the operative knee joints (25 in each group), including the range of motion, joint infection, and intra-articular structures (cartilage, meniscus).
2. We evaluated the continuity and tension of the ACL grafts (25 in each group).
3. The ACL remnants in group 1 were first identified by their colors, as well as the incorporation results with the ACL grafts. Then, the structural integrity and the remnant-to-graft healing capacity of the ACL remnants were further evaluated.
4. The structural integrity of the ACL remnants in group 1 ($n = 25$) was categorized into 3 categories by

use of a new grading system modified from that reported by Ahn et al.¹⁹: grade A, good (well-maintained continuity with an adequate amount of tissue and tension on probing); grade B, fair (fairly maintained continuity with thin and slack fiber detected); or grade C, poor (no remnant left in situ).

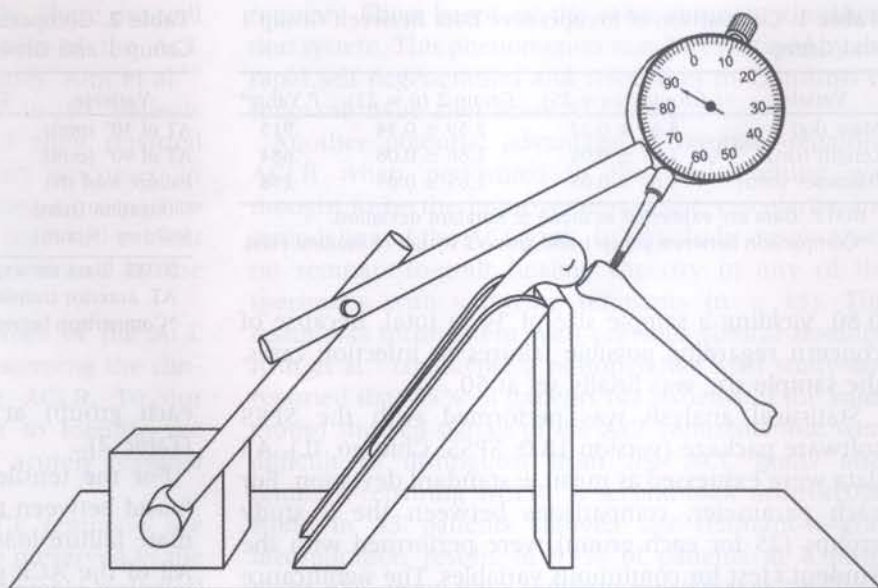
5. The remnant-to-graft healing capacity was assessed among the specimens with surviving remnants (grades A and B for structural integrity, in which the continuity of the remnants was maintained between the tibial and femoral ACL insertion sites) by 2 observers. A scaled probe was placed on the mid-substance portion as well as the tibial and femoral insertion sites of the ACL remnants. One of the observers applied a mild anterior force onto the probe to stretch the ACL remnants while the other observer carefully investigated the interval between the remnant and the graft from the lateral view of the specimens. According to the results of our pilot study, the healing capacity was also divided into 3 levels: grade A, good (complete healing with no remnant-to-graft interval); grade B, fair (partial healing with a detectable remnant-to-graft interval but not through the entire length of the graft); or grade C, poor (no healing with an obvious remnant-to-graft interval through the entire length of the graft).

Biomechanical Tests

In this study we designed 2 biomechanical tests: (1) the anterior tibial translation test and (2) the tensile test. All specimens were wrapped in saline solution-soaked gauze and stored at -4°C until testing. Before the biomechanical tests, the specimens were thawed overnight at 4°C .

For the anterior tibial translation test, the surrounding muscles were carefully removed to exclude experimental errors produced by different muscle strengths among specimens. Care was taken to avoid damaging

Fig 2. The anterior translation test was performed using a customized arthrometer.



the joint capsule and ligaments. During the entire preparation process, all the specimens were maintained in saline solution—soaked gauze. The preassembled customized measurement device, which was similar to the device reported by Nikolaou et al.,²² was placed on a flat testing table (Fig 2). A dial indicator with 0.01-mm resolution (Mitutoyo dial indicator 2050; Mitutoyo, Tokyo, Japan) was fixed to the customized measurement device. A small drill hole was made on the tibial tuberosity, and the drill hole was used as the base point for the measurements. The anterior tibial translation test at 30° and 90° of knee flexion was performed in neutral rotation of the tibia, with a 15-N drawer force applied perpendicularly to the long axis of the tibia. Three measurements were taken for each test by the same examiner. The final results were recorded as the mean values of the 3 side-to-side differences between the operative and normal sides.

To assess the reliability of the customized measurement device for the anterior tibial translation, a pilot study was designed. For the 2 knee flexion angles, 2 authors performed each measurement twice, with a 2-day interval between measurements. A total of 30 specimens were randomly selected from both groups (15 for each group). The intraclass correlation coefficients for intraobserver and interobserver reliability were 0.91 and 0.86, respectively, at 30° of knee flexion and 0.88 and 0.85, respectively, at 90° of knee flexion, indicating high reliability.

For the tensile test, as described previously in the literature,²³ the joint capsule and peripheral ligaments were carefully resected from the tibial and femoral attachment sites, leaving only the ACL remnants and grafts intact. The medial and lateral menisci and their accessory ligaments were also removed. The tensile

test was performed on a tensile tester (858 Mini Bionix II; MTS Systems, Eden Prairie, MN). Before the test, the specimen was fixed with 4 transverse pins between the custom-designed U-shaped clamps with 2 pins on each side. Care was taken to ensure that the specimens were fixed at 30° of knee flexion to keep the direction of the tensile force in line with the direction of the ACL fibers. The fixed specimens were applied with a preload of 2 N. Pre-tensioning of the graft was accomplished by stretching it 3 times for up to 0.5 mm at a speed of 0.1 mm/s. The tensile test was started at a crosshead speed of 1 mm/s. The force resolution of the tensile tester was 0.1 N. A load-displacement curve was recorded and amended by the computer for calculating stiffness, ultimate failure load, and elongation at failure of the specimens. The failure mode was determined by visual inspection. We defined the failure mode as bony avulsion, pulling out from the bone tunnels (either from the femoral or tibial side), and midsubstance tears.

Statistical Analysis

An a priori power analysis was performed before the study to estimate the sufficient sample size. Biomechanical tests were the main outcome measurements in our study. The following values (expected difference and standard deviation) for the anterior tibial translation test at 30° and 90° of knee flexion were obtained from the pilot study of 8 rabbits (4 rabbits for each group, but they were not included in the final study): 0.20 mm (SD, 0.20 mm) and 0.25 mm (SD, 0.25 mm), respectively. Sample sizes were calculated by use of SAS software (version 9.13; SAS Institute, Cary, NC) for each value to detect the previously mentioned differences between groups with an α of .05 and a power of

Table 1. Comparison of Preoperative Data Between Group 1 and Group 2

Variable	Group 1 (n = 25)	Group 2 (n = 25)	P Value*
Mass (kg)	3.64 ± 0.28	3.59 ± 0.34	.915
Length (cm)	1.67 ± 0.06	1.66 ± 0.08	.684
Diameter (mm)	1.68 ± 0.08	1.65 ± 0.09	.258

NOTE. Data are expressed as mean ± standard deviation.

*Comparison between group 1 and group 2 by use of Student *t* test.

0.80, yielding a sample size of 34 in total. Because of concern regarding possible failures or infection cases, the sample size was finally set at 50.

Statistical analysis was performed with the SPSS software package (version 18.0; SPSS, Chicago, IL). All data were expressed as mean ± standard deviation. For each parameter, comparisons between the 2 study groups (25 for each group) were performed with the Student *t* test for continuous variables. The significance level was set at .05.

Results

There were no significant differences between the 2 groups regarding the mass of the animals or the lengths and cross-sectional diameters of the ACL autografts (Table 1). On the basis of these facts, we believed that the comparisons in our study would be valid.

Macroscopic Evaluations

1. There were no signs of joint infection and no loss of range of motion in flexion or extension for any specimen. There were no obvious degenerative changes of the joint cartilage and meniscal tears (25 in each group).
2. All of the ACL grafts showed satisfactory continuity and tension (25 in each group).
3. All the ACL remnants were easily identified by obviously different colors and no incorporation results compared with the ACL grafts.
4. Regarding the structural integrity of the ACL remnants in group 1 (n = 25), 10 of the ACL remnants (40%) were found to have a structural integrity of grade A, 5 (20%) were grade B, and 10 (40%) were grade C.
5. The remnant-to-graft healing capacity among the surviving remnant specimens (grades A and B for structural integrity, in which the continuity of the remnants was maintained between the tibial and femoral ACL insertion sites, n = 15) was found to be grade C in all cases.

Biomechanical Tests

For the anterior tibial translation test, no significant differences were found between the 2 groups (25 in

Table 2. Comparison of Biomechanical Outcomes Between Group 1 and Group 2

Variable	Group 1 (n = 25)	Group 2 (n = 25)	P Value*
AT of 30° (mm)	1.53 ± 0.26	1.65 ± 0.33	.15
AT of 90° (mm)	1.55 ± 0.31	1.54 ± 0.41	.91
Failure load (N)	58.1 ± 11.4	56.7 ± 13.5	.11
Elongation (mm)	3.82 ± 0.47	3.81 ± 0.51	.92
Stiffness (N/mm)	15.5 ± 3.9	15.1 ± 4.1	.66

NOTE. Data are expressed as mean ± standard deviation.

AT, anterior translation.

*Comparison between group 1 and group 2 by use of Student *t* test.

each group) at either 30° or 90° of knee flexion (Table 2).

For the tensile test, no significant differences were found between the 2 groups in terms of stiffness, ultimate failure load, and elongation at failure (Table 2). All of the ACL grafts (25 in each group) failed at the midsubstance portion without being pulled out from the bone tunnel.

Identical statistical analyses were performed between the specimens with grade A remnant structural integrity (n = 10) in group 1 and the specimens in group 2 (n = 25), and no significant differences were found with respect to the outcomes of the anterior tibial translation and tensile tests (Table 3).

Discussion

The most important findings of this study were as follows: (1) There was a high postoperative remnant resorption rate (40%) and low remnant-to-graft healing capacity in the acutely repaired ACL remnants, which were far beyond our expectations. (2) The remnant-repairing ACLR group produced similar postoperative biomechanical results to the conventional ACLR group. Our hypotheses were shown to be incorrect.

We should note that the remnant-repairing technique applied in this study was quite different from the selective ACL augmentation technique, which is indicated

Table 3. Comparison of Biomechanical Outcomes Between Grade A Specimens in Group 1 and Group 2 Specimens

Variable	Grade A in Group 1* (n = 10)	Group 2 (n = 25)	P Value†
AT of 30° (mm)	1.52 ± 0.20	1.65 ± 0.33	.89
AT of 90° (mm)	1.56 ± 0.15	1.54 ± 0.41	.98
Failure load (N)	59.1 ± 9.2	56.7 ± 13.5	.48
Elongation (mm)	3.78 ± 0.54	3.81 ± 0.51	.71
Stiffness (N/mm)	15.9 ± 3.4	15.1 ± 4.1	.84

NOTE. Data are expressed as mean ± standard deviation.

AT, anterior translation.

*Specimens with grade A structural integrity outcome (well-maintained continuity of ACL remnant between femoral and tibial insertion sites).

†Comparison between grade A and group 2 by use of Student *t* test.

for partial ACL tears.^{13,14,24} Currently, there are still controversies concentrating on the role of the ACL remnants in treating complete ACL tears. Ahn et al.¹⁹ performed remnant-repairing ACLR in 53 patients who had complete ACL tears, and they reported favorable postoperative clinical stability outcomes. In contrast, Hong et al.⁹ recently conducted a prospective comparative study and concluded that no evident biomechanical advantages could be confirmed by the remnant-repairing ACLR.

The postoperative structural outcomes of the ACL remnants should be a major issue concerning the clinical outcomes of remnant-repairing ACLR. To our knowledge, this study was the first to identify the postoperative structural outcomes of acutely repaired ACL remnants.

Some authors believe that the ACL remnants are supposed to be more reasonable to be preserved in the acute setting, especially given their favorable biological healing results. Denti et al.¹⁸ reported a decreased number of mechanoreceptors in completely ruptured ACL remnants over time. Schoene et al.²⁵ also confirmed that the ACL-hamstring reflex, which was a reliable measurement of the proprioceptive function of the knee joint, decreased more rapidly as time passed after ACL injury. Ahn et al.¹⁹ found that patients with a shorter period from injury to surgery had better synovial coverage and graft incorporation outcomes after remnant-repairing ACLR on postoperative magnetic resonance imaging (MRI). In our study the survival rate of the acutely repaired ACL remnants (maintained continuity between the tibial and femoral insertion sites) was found to be only 60%, which was far lower than we anticipated. The different healing outcomes among studies may be attributed to the specific kind of ACL injury pattern created in our study—the acute complete femoral ACL detachment model. As we have learned from the previous studies,²¹ there were differences between the ACL detachment and the ACL rupture models in terms of the natural ACL healing capacities. Interestingly, our results (40% of specimens with no remnant left) were also comparable with those studies focusing on the outcomes of remnants after subacute or chronic ACL tears. In 2005 Crain et al.²⁶ first classified the patterns of the ACL remnants into 4 types based on their arthroscopic findings: the type with healing of the posterior cruciate ligament, the type with healing of the roof of the intercondylar notch, the type with healing of the medial wall of the lateral femoral condyle, and the type with no visible remnant fibers. They also reported a 42% incidence of cases with no visible remaining ACL remnants in a group of 48 consecutive patients who underwent ACLR at a mean of 78 weeks (range, 5 to 676 weeks) after the primary ACL tears occurred. In addition, Nakamae et al.²⁷ found that 50% of chronic ACL tear cases had no visible ACL

remnant fibers based on the same remnant classification system. This phenomenon may be explained by the rapid self degeneration and resorption mechanisms of remnant tissue after acute ACL tears.^{21,28}

Another potential advantage of remnant-repairing ACLR when performed in the acute setting was thought to be the improvement of the vascularity and remodeling of the ACL graft. In this study we observed no remnant-to-graft healing capacity in any of the specimens with surviving remnants ($n = 15$). This result was inconsistent with previous clinical findings. Ahn et al.⁷ conducted a postoperative MRI study and reported that 85% of patients (41 patients in the study group) showed signals of the ACL remnants that were difficult to distinguish from the ACL grafts after remnant-repairing ACLR. A second-look arthroscopic study in 33 patients showed fair remnant-to-graft incorporation results in 91% of patients at a minimum of 2 years after remnant-repairing ACLR.¹⁹ On the basis of judging critically from the details, MRI was relatively unable to evaluate the real remnant-to-graft healing status, although homogeneous signal intensities were presented. On second-look arthroscopy, the ACL graft-covered synovium still prevented the authors from detecting the actual healing capacity between the ACL remnant and the graft.

It appears that even with the remnants repaired in the acute setting, the postoperative outcomes of the ACL remnants, including the survival rate and the remnant-to-graft healing capacity, would not be improved as we expected.

Concerning the postoperative biomechanical outcomes, a recent study performed by Wu et al.²⁹ reported that ACLR with preservation of the ACL remnant attachment significantly improved the postoperative biomechanical properties of the knee joint compared with conventional ACLR in a rabbit model. In contrast, Jung et al.³⁰ conducted a clinical study comparing remnant-repairing ACLR versus ACLR with remnant preservation only and reported that no significant differences could be found between groups in terms of knee stability outcomes postoperatively. In our study the low remnant survival rate (60%) and the remnant-to-graft healing capacity showed a poorly maintained remnant structural outcome after the remnant-repairing ACLR, which could lead to similar postoperative biomechanical outcomes between groups. Moreover, the similar biomechanical results between the specimens with grade A structural integrity ($n = 10$) in group 1 and the specimens in group 2 ($n = 25$) could be explained by the following 2 reasons: (1) the dominant postoperative stability was provided by the ACL graft, and (2) the strength of the ACL remnants was not great enough to contribute a significant biomechanical difference. The 2 previous studies and our study all provide important information for us to understand the potential biomechanical advantages of performing the

remnant-preserving ACLR. However, with different remnant-preservation techniques applied and the distinct research groups compared among studies, it is still difficult to reach a final conclusion about whether the remnant-repairing ACLR will significantly improve postoperative knee stability outcomes.

The acutely repaired ACL remnants presented in our study showed a high resorption rate, a low healing capacity, and poor biomechanical properties. Moreover, we believed that the previously mentioned advantages of repairing the ACL remnants, such as the increased vascularity and the improved proprioceptive function, should be based on a well-survived and adequately healed ACL remnant after the remnant-repairing ACLR.

Limitations

There were several limitations in this study. First, the test data are from rabbits, which cannot be directly transferred to humans. Second, the metabolic process varies substantially between rabbits and humans, which could affect the time-dependent remnant healing process. As a solution, we selected a 12-week period as the endpoint of our study for the following reasons: (1) a number of studies reported that 12 weeks would be long enough for a mature graft-to-bone healing process in the rabbit ACLR model,^{20,21,31-33} and (2) the purpose of our study was to investigate short-term biomechanical outcomes. Third, the remnant-to-graft healing capacity evaluation in this study was simply based on macroscopic evaluations, which lacked convincing histologic evidence. Fourth, to further elucidate the benefit of the remnant-repairing technique, a control group with remnant repaired alone would be ideal. Finally, what we really created was a complete femoral ACL "detachment" but not a "rupture" model. Attention should be drawn to the injury pattern of the ACL remnant because there were significant differences between these 2 distinct injury patterns in terms of the natural healing capacity.²¹

Conclusions

In our rabbit model of ACL femoral detachment, the acutely repaired ACL remnants showed a high resorption rate, low healing capacity, and poor biomechanical properties. The acute remnant-repairing ACLR had no evident superiority over the conventional ACLR in rabbits.

References

1. Kruse LM, Gray B, Wright RW. Rehabilitation after anterior cruciate ligament reconstruction: A systematic review. *J Bone Joint Surg Am* 2012;94:1737-1748.
2. Li S, Chen Y, Lin Z, Cui W, Zhao J, Su W. A systematic review of randomized controlled clinical trials comparing hamstring autografts versus bone-patellar tendon-bone autografts for the reconstruction of the anterior cruciate ligament. *Arch Orthop Trauma Surg* 2012;132:1287-1297.
3. Tiamklang T, Sumanont S, Foocharoen T, Laopaiboon M. Double-bundle versus single-bundle reconstruction for anterior cruciate ligament rupture in adults. *Cochrane Database Syst Rev* 2012;11:CD008413.
4. Panni AS, Milano G, Tartarone M, Demontis A, Fabbriani C. Clinical and radiographic results of ACL reconstruction: A 5- to 7-year follow-up study of outside-in versus inside-out reconstruction techniques. *Knee Surg Sports Traumatol Arthrosc* 2001;9:77-85.
5. Kazusa H, Nakamae A, Ochi M. Augmentation technique for anterior cruciate ligament injury. *Clin Sports Med* 2013;32:127-140.
6. Papalia R, Franceschi F, Vasta S, Di Martino A, Maffulli N, Denaro V. Sparing the anterior cruciate ligament remnant: Is it worth the hassle? *Br Med Bull* 2012;104:91-111.
7. Ahn JH, Lee SH, Choi SH, Lim TK. Magnetic resonance imaging evaluation of anterior cruciate ligament reconstruction using quadrupled hamstring tendon autografts: Comparison of remnant bundle preservation and standard technique. *Am J Sports Med* 2010;38:1768-1777.
8. Ahn JH, Lee YS, Ha HC. Anterior cruciate ligament reconstruction with preservation of remnant bundle using hamstring autograft: Technical note. *Arch Orthop Trauma Surg* 2009;129:1011-1015.
9. Hong L, Li X, Zhang H, et al. Anterior cruciate ligament reconstruction with remnant preservation: A prospective, randomized controlled study. *Am J Sports Med* 2012;40:2747-2755.
10. Lee BI, Min KD, Choi HS, et al. Immunohistochemical study of mechanoreceptors in the tibial remnant of the ruptured anterior cruciate ligament in human knees. *Knee Surg Sports Traumatol Arthrosc* 2009;17:1095-1101.
11. Dhillon MS, Bali K, Vasistha RK. Immunohistological evaluation of proprioceptive potential of the residual stump of injured anterior cruciate ligaments (ACL). *Int Orthop* 2010;34:737-741.
12. Bali K, Dhillon MS, Vasistha RK, Kakkar N, Chana R, Prabhakar S. Efficacy of immunohistological methods in detecting functionally viable mechanoreceptors in the remnant stumps of injured anterior cruciate ligaments and its clinical importance. *Knee Surg Sports Traumatol Arthrosc* 2012;20:75-80.
13. Adachi N, Ochi M, Uchio Y, Sumen Y. Anterior cruciate ligament augmentation under arthroscopy. A minimum 2-year follow-up in 40 patients. *Arch Orthop Trauma Surg* 2000;120:128-133.
14. Ochi M, Adachi N, Uchio Y, et al. A minimum 2-year follow-up after selective anteromedial or posterolateral bundle anterior cruciate ligament reconstruction. *Arthroscopy* 2009;25:117-122.
15. Demirag B, Ermutlu C, Aydemir F, Durak K. A comparison of clinical outcome of augmentation and standard reconstruction techniques for partial anterior cruciate ligament tears. *Eklem Hastalik Cerrahisi* 2012;23:140-144.
16. Yoon KH, Bae DK, Cho SM, Park SY, Lee JH. Standard anterior cruciate ligament reconstruction versus isolated single-bundle augmentation with hamstring autograft. *Arthroscopy* 2009;25:1265-1274.
17. Song GY, Zhang H, Zhang J, et al. The anterior cruciate ligament: To leave it or not? *Arthroscopy* 2013;29:1253-1262.

18. Denti M, Monteleone M, Berardi A, Panni AS. Anterior cruciate ligament mechanoreceptors. Histologic studies on lesions and reconstruction. *Clin Orthop Relat Res* 1994;308:29-32.
19. Ahn JH, Wang JH, Lee YS, Kim JG, Kang JH, Koh KH. Anterior cruciate ligament reconstruction using remnant preservation and a femoral tensioning technique: Clinical and magnetic resonance imaging results. *Arthroscopy* 2011;27:1079-1089.
20. Papachristou G, Nikolaou VS, Efstathopoulos N, et al. ACL reconstruction with semitendinosus tendon autograft without detachment of its tibial insertion: A histologic study in a rabbit model. *Knee Surg Sports Traumatol Arthrosc* 2007;15:1175-1180.
21. Hefti FL, Kress A, Fasel J, Morscher EW. Healing of the transected anterior cruciate ligament in the rabbit. *J Bone Joint Surg Am* 1991;73:373-383.
22. Nikolaou VS, Efstathopoulos N, Sourlas I, Pilichou A, Papachristou G. Anatomic double-bundle versus single-bundle ACL reconstruction: A comparative biomechanical study in rabbits. *Knee Surg Sports Traumatol Arthrosc* 2009;17:895-906.
23. Sun L, Zhou X, Wu B, Tian M. Inhibitory effect of synovial fluid on tendon-to-bone healing: An experimental study in rabbits. *Arthroscopy* 2012;28:1297-1305.
24. Ochi M, Adachi N, Deie M, Kanaya A. Anterior cruciate ligament augmentation procedure with a 1-incision technique: Anteromedial bundle or posterolateral bundle reconstruction. *Arthroscopy* 2006;22:461-463.
25. Schoene M, Spengler C, Fahrbacher B, Hartmann J, Melnyk M, Friemert B. The reliability of a method for measuring the anterior cruciate ligament-hamstring reflex: An objective assessment of functional knee instability. *Knee Surg Sports Traumatol Arthrosc* 2009;17:1107-1116.
26. Crain EH, Fithian DC, Paxton EW, Luetzow WF. Variation in anterior cruciate ligament scar pattern: Does the scar pattern affect anterior laxity in anterior cruciate ligament-deficient knees? *Arthroscopy* 2005;21:19-24.
27. Nakamae A, Ochi M, Deie M, et al. Biomechanical function of anterior cruciate ligament remnants: How long do they contribute to knee stability after injury in patients with complete tears? *Arthroscopy* 2010;26:1577-1585.
28. Murray MM, Martin SD, Martin TL, Spector M. Histological changes in the human anterior cruciate ligament after rupture. *J Bone Joint Surg Am* 2000;82:1387-1397.
29. Wu B, Zhao ZQ, Li SG, Sun L. Preservation of remnant attachment improves graft healing in a rabbit model of anterior cruciate ligament reconstruction. *Arthroscopy* 2013;29:1362-1371.
30. Jung YB, Jung HJ, Siti HT, et al. Comparison of anterior cruciate ligament reconstruction with preservation only versus remnant tensioning technique. *Arthroscopy* 2011;27:1252-1258.
31. Lim JK, Hui J, Li L, Thambyah A, Goh J, Lee EH. Enhancement of tendon graft osteointegration using mesenchymal stem cells in a rabbit model of anterior cruciate ligament reconstruction. *Arthroscopy* 2004;20:899-910.
32. Park MJ, Lee MC, Seong SC. A comparative study of the healing of tendon autograft and tendon-bone autograft using patellar tendon in rabbits. *Int Orthop* 2001;25:35-39.
33. Soon MY, Hassan A, Hui JH, Goh JC, Lee EH. An analysis of soft tissue allograft anterior cruciate ligament reconstruction in a rabbit model: A short-term study of the use of mesenchymal stem cells to enhance tendon osteointegration. *Am J Sports Med* 2007;35:962-971.